

12. Nguyen TT, Tsukada H, Breeze J, Masouros SD. The Critical Role of a Backing Material in Assessing the Performance of Soft Ballistic Protection. *Human Factors and Mechanical Engineering for Defense and Safety*. 2022;6:13. doi: 10.1007/s41314-022-00052-1
13. Stefanopoulos PK, Hadjigeorgiou GF, Filippakis K, Gyftokostas D. Gunshot wounds: a review of ballistics related to penetrating trauma. *Journal of Acute Disease*. 2014;3(3):178–85. doi: 10.1016/S2221-6189(14)60041-X
14. Stevenson T, Carr DJ, Gibb IE, Stapley SA. Preliminary effect of projectile yaw on extremity gunshot wounding in a cadaveric animal model: a serendipitous study. *International Journal of Legal Medicine*. 2020;134(3):1149–57. doi: 10.1007/s00414-020-02271-7
15. Wightman G, Wark K, Thomson J. The interaction between clothing and air weapon pellets. *Forensic science international*. 2015;246:6–16. doi: 10.1016/j.forsciint.2014.10.039

Стаття надійшла 16.11.2021 р.

DOI 10.26724/2079-8334-2022-4-82-235-240

UDC 616.716.4:615.015

V.S. Pikalyuk, S.O. Mostovoy<sup>1</sup>, M.V. Peshkov<sup>1</sup>, G.F. Tkach<sup>1</sup>,  
T.Ya. Shevchuk, L.S. Aponchuk, O.V. Usova  
Lesya Ukrainka Volyn National University, Lutsk  
<sup>1</sup>Sumy State University, Sumy

### MORPHOGENESIS OF THE ZERO-STAGE OSTEONECROSIS FORMATION OF THE LOWER JAW BASED ON THE USE OF AMINOBISPHOSPHONATES

e-mail: pikaluk@ukr.net

The dynamics of morphostructural changes in the mandibular bones of laboratory white rats after a 3-month exposure to pamidronic acid at the dose of 63 mg/kg was studied. Light microscopy methods were used, including qualitative and quantitative characteristics in assessing the structural state of the bone through the parameters that characterize the histoarchitectonics of the lower jaw using indices and their abbreviations proposed by the committee on histomorphometric nomenclature of American Society for Bone and Mineral Research. Three new functional indices for assessing physiological processes in bones were studied. It was established that administration of pamidronic acid to laboratory white rats for 3 months leads to myelofibrosis and focal osteosclerosis with osteodystrophic changes, similar to the processes that develop in ossifying osteitis.

**Key words:** aminobisphosphonate, osteonecrosis, osteocytic osteolysis, lower jaw.

В.С. Пикалюк, С.О. Мостовой, М.В. Пешков, Г.Ф. Ткач, Т. Я. Шевчук,  
Л. С. Апончук, О.В. Усова

### МОРФОГЕНЕЗ ФОРМУВАННЯ НУЛЬОВОЇ СТАДІЇ ОСТЕОНЕКРОЗУ НИЖНЬОЇ ЩЕЛЕПИ НА ТЛІ ВИКОРИСТАННЯ АМІНОБІСФОСФОНАТІВ

Вивчено динаміку морфоструктурних змін нижньощелепних кісток лабораторних білих щурів при 3-місячному впливі памідронові кислоти в дозі 63 мг/кг. Використовували методи світлової мікроскопії, включаючи якісні і кількісні характеристики оцінки структурного стану кістки через параметри, які характеризують гістоархітектоніку нижньої щелепи з використанням показників і їхніх аббревіатур, запропонованих комітетом з гістоморфометричної номенклатури Американського товариства дослідження кісток та мінералів. Досліджені три нових функціональних показники для оцінки фізіологічних процесів у кістках. Установлено, що введення памідронові кислоти лабораторним білим пацюкам протягом 3 місяців веде до мієлофіброзу й вогнищевого остеосклерозу з остеодистрофічними змінами подібно до процесів, які розвиваються при осифікуючому оститі.

**Ключові слова:** амінобісфосфонат, остеонекроз, остеоцитарний остеоліз, нижня щелепа.

*The study is a fragment of the research project “Morphofunctional aspects of the body homeostasis impairment”, state registration No. 0118U006611.*

Bisphosphonates have been known since the middle of the 11th century. It is worth noting that these compounds are able to prevent significant loss of bone mass and are used for palliative therapy in bone metastases of malignant neoplasms, which are combined with hypercalcemia syndrome. Such side effects as osteonecrosis of the jaws come to the fore, which is particularly pronounced when patients use aminobisphosphonate mixtures. Data from the literature indicate a certain uncertainty in the morphological justification of their negative impact on bone tissue. Clinical side syndromes are manifested in the form of osteonecrosis of the jaws and are defined as a condition characterized by exposure of the bone of the lower and (or) upper jaw, which persists for 8 weeks in the absence of previous radiation or metastases. A similar wording characterizes the state of infection of the jawbones when the integrity of the mucous membranes is violated, which is confirmed by morphological studies [5, 8, 11].

Morphological signs of the negative effects of aminobisphosphonates preceding clinical manifestations, are revealed using experimental models of the jaws' osteonecrosis [13, 14, 15,] they are not complete, because when modeling this disease, the authors used short periods of exposure to medicinal substances of the aminobisphosphonate group, and also introduced into the experimental model cytostatic or hormonal drugs with an obligatory element of traumatization, which created conditions for the development of osteonecrotic processes of purulent-inflammatory genesis. In addition, only low (therapeutic) doses of drugs of the aminobisphosphonate group were used in the above studies.

**The purpose** of the study was to investigate the dynamics of morphological changes in the mandibular bones of laboratory white rats under long-term (1 and 3 months) exposure to high doses of aminobisphosphonates.

**Materials and methods.** Experimental studies were performed on 40 white outbred male rats with a body weight of 150–200 grams. The animals were divided into four equal groups. The first and the third control groups included the animals that were injected intraperitoneally with 1.0 ml of physiological solution once a day for 30 and 90 days to create equivalent experimental conditions.

The second and fourth experimental groups consisted of animals that were intraperitoneally injected with the drug of the aminobisphosphonate group pamired (pamidronic acid) at the dose of 63 mg/kg once a day for 30 and 90 days. The dose in the previous studies performed on tubular bones of white laboratory rats causes many side effects with long-term use [12].

The animals were sacrificed under ketamine anesthesia at the rate of 4.4 mg/kg by decapitation in accordance with the international rules for conducting work with experimental animals [10]. The material for the study was the skeletonized lower jaws of rats, fixed in 10 % neutral buffered formalin for 72 hours, decalcified in a 14 % Trilon B solution, buffered to pH 7.0. The procedure was carried out using isopropanol and mineral oil, tissues were embedded in paraffin [3, 4, 9]. 3  $\mu$ m thick paraffin sections were cut on a Leica RM2245 rotary microtome (Germany) with Surgipath DB80LX blades (USA). Sections were stained with hematoxylin and eosin according to Romanovsky-Giemse and Masson-Goldner. Morphometric studies were carried out with a computer morphometric complex, which includes an Olympus CX-31 microscope, an Olympus C5050Z digital camera (China) at the magnification of 100, 400, 1000.

The article uses indices and their abbreviations proposed by the histomorphometric nomenclature committee at the American Society of Bone and Mineral Research Histomorphometry Nomenclature Committee [9]. The parameters characterizing the microarchitectonics of trabecular bone were determined: the volume of cancellous matter (Cn-BV/TV) – the percentage of bone matter between the cortical layers (%), the thickness of trabeculae (Tb.Th.,  $\mu$ m), the separation of trabeculae (Tb.Sp.,  $\mu$ m), the number of trabeculae (Tb.N., in terms of 1 mm<sup>2</sup>).

Then a node-strut analysis was performed [11], which includes the calculation of the connections (N.Nd.) and terminations (N.Tm.) number in 1 mm<sup>2</sup>, the distance between connections (Nd.Nd.), between terminations ( Tm.Tm.) and from the connection to the termination (Nd.Tm.). Connections were understood as places of trabeculae's branching, and terminations were understood as freely located ends of trabeculae as part of the trabecular network. At the same time, the state of the bone substance was assessed according to the following parameters: BDS – the percentage of the bone substance surface subjected to necrosis; OS/BS – osteoid surface; the percentage of the total perimeter of the spongy substance covered by osteoid; OV/BV – osteoid volume; the percentage of spongy substance that did not undergo calcification, as well as NOc - the number of osteoclasts in 1 mm<sup>2</sup>.

To assess physiological processes, we studied three functional indices, which we assigned the following abbreviations: OOL (osteocytic osteolysis, osteocytic osteolysis) – the percentage of the bone surface covered with osteocytic lacunae with signs of lytic processes; FB (fibrosis of the bone marrow) is the percentage of the surface of the bone marrow cavity exposed to fibrosis; AOS (area of osteosclerosis) is the percentage of the bone surface exposed to osteosclerosis [2]. For the overall assessment of the degree of trabeculae density in the spongy substance, the stellate volume of the bone marrow cavity V\* was determined [3].

Statistical processing of the study results was carried out using the methods of parametric statistics in the environment of the STATISTICA 10.0 software (StatSoft, USA), in order to identify differences between the groups. The mean arithmetic value of each index in each group  $\bar{X}$  and its mean squared error  $m\bar{X}$  were calculated. The analysis of conformity of the signs distribution type to the law of normal distribution was carried out using the Shapiro-Wilk test ( $p \geq 0.05$ ).

Homogeneity of variances was assessed using Levene's test. Since the distribution of feature values in the groups corresponded to the normal, but heterogeneity of variances was found, the significance of differences was assessed by the non-parametric Mann-Whitney test. At the level of  $p \leq 0.05$ , differences in groups were considered statistically significant.

**Results of the study and their discussion.** The structural organization of the bone tissue of the lower jaw in animals of the both control groups corresponded to age. Cellular and non-cellular elements were located in a characteristic manner, which corresponded to the normal anatomical structure and can serve as a control for the corresponding experimental groups. The morphometric indices calculated by us are presented in Table 1. In group 2 of animals exposed to pamidronic acid for 30 days, a heterogeneous pattern of the histostructure disturbance in the mandible bone was revealed.

Table 1

**Histomorphometric indices of the outer and inner surfaces of the lower jaw in laboratory white rats ( $\bar{X} \pm m\bar{X}$ ) (n=6)**

indices \ Groups	First	Second	Third	Fourth
Cn-BV/TV, %	41.98±0.7	53.5±1.97%	42.75±0.8 %	62.48±1.9%
Tb.N, unit/mm <sup>2</sup>	13.49±0.36	5.5±0.34*	14.17±0.75*	17.2±0.63**
Tb.Th, mcm	77.21±1.69	113.47±0.85*	82.4±3.74	83.95±2.96**
Tb.Sp, mcm	63.28±1.93	32.86±0.59*	67.78±2.17	51.53±9.42**
N.Nd, unit/mm <sup>2</sup>	8.91±0.83	6.17±0.23*	9.30±0.56	8.5±0.43**
N.Tm, unit/mm	6.60±0.60	4.83±0.1*	7.52±0.75	12.5±1.35**
Nd.Nd, mcm	285.95±1.25	173.5±0.64*	292.38±1.04	351.1±2.86**
Nd.Tm, mcm	168±2.15	132.7±1.01*	171±0.92	232.7±1.01**
Tm.Tm, mcm	49.18±0.7	41.38±0.66*	51.42±1.47	64.03± 1.87**
FBM,%	2.41±0.21%	23.41±0.56*	3.19±0.12% *	73.41±0.54**
OS/BS %	4.26±0.27	13.79±0.55*	3.69±0.3	15.45±1.43**
OV/BV, %		2.78±0.14		4.27±0.16
OOL %	3.53±0.12%		2.22±0.15*	
BDS		14.79±0.59		24.85±0.56
AOS, %				7.07±0.33
N.Oc unit/mm <sup>2</sup>	3.18±0.22	2.0±0.42*	2.7±0.73	4.5±0.32**
V mm <sup>2</sup>	0.30±0.01	0.03±0.0005*	0.35±0.02	0.02±0.0003**

Note: \* p < 0,05 in comparison to the indices of group 1 (cotrol)\*\* in comparison to the indices of group 3 (control)

The bone beams were sharply thickened, and a trabecular network with bone marrow cavities of small and medium sizes was formed between them. A qualitatively determined increase in the processes of appositional bone formation was confirmed by all histomorphometric indices that characterized the size of the bone array (fig. 1A).

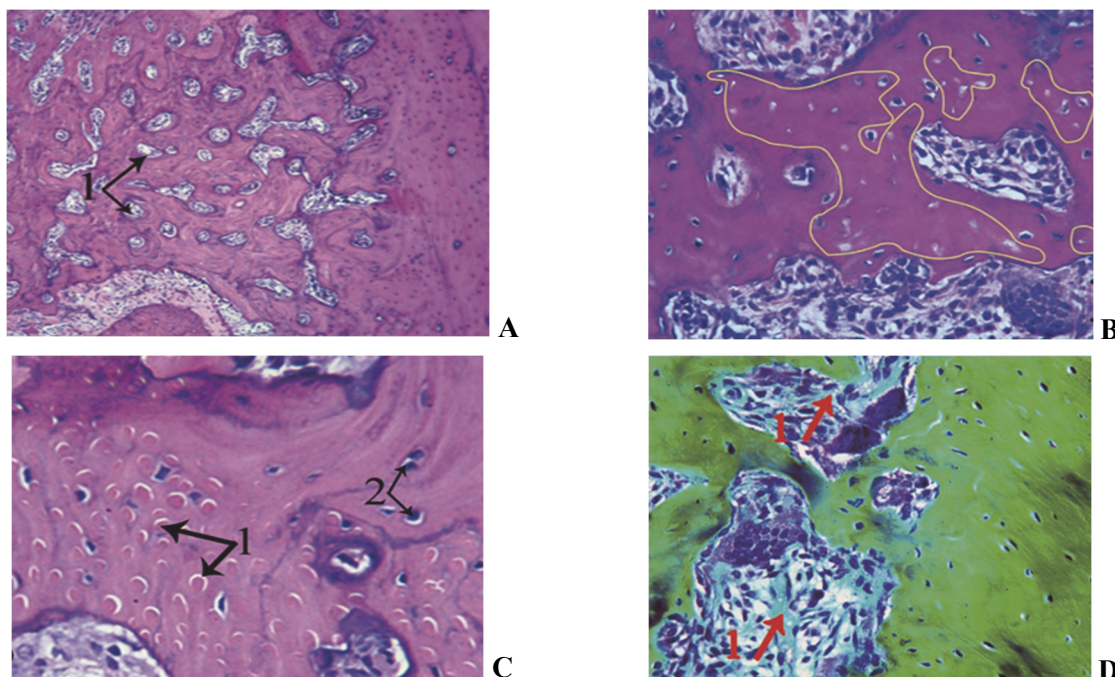


Fig. 1. The structure of bone tissue of the lower jaw after exposure to pamidronic acid for 30 days. A. The structure of the trabecular network. Reduction of bone marrow spaces by appositional growth of the bone tissue (1). Staining with hematoxylin and eosin. x 100. B. Foci of aseptic osteonecrosis (highlighted in yellow). Staining with hematoxylin and eosin. x 100. C. Zone of osteocytic bone remodeling: honeycomb structures filled with protein masses (1); enlarged lacunae with hypertrophied osteocytes (2). Staining with hematoxylin and eosin, x 400; D. Growth of coarse fiber connective tissue in bone marrow cavities. Masson-Goldner staining, x 400.

A pronounced uneven basophilia was observed in the main substance of the bone. Newly formed bone beams were stained lighter and contained a larger number of osteocytes. Discomplexation of newly formed bone beams with chaotic branching was observed in some areas. In part of the trabeculae, foci of aseptic osteonecrosis were found, including three or more empty lacunae, or with osteocytes in a state of karyopyknosis and karyolysis, as well as lacunae containing acellular granular-protein masses. Areas of osteocytic osteolysis, as a rule, were adjacent to the foci of necrosis, so a conventional demarcation line during histomorphometric analysis was drawn between lacunae containing necrotic protein masses and lacunae with living osteocytes. Empty lacunae were found only found in areas with altered osteocytes, which permitted to exclude artifacts that could arise in the process of decalcification and preparation of specimens (fig. 1B). The areas of osteocytic osteolysis themselves were significantly larger in size compared to the first control group, consisted of enlarged lacunae with periosteocytic basophilia and lacunae containing protein masses, forming zones of nostril structures of the “lacunary honeycomb” type (fig. 1B). Along the edge of the trabeculae, the lacunae formed small recesses with fallen osteocytes and bay-like depressions, which arise when several previously united osteocyte lacunae are united. The protein content of lacunae has a bright color: from reddish-pink to yellowish-brown. In the lacunae, both on the periphery of the trabeculae and on their surface, the protein masses are impregnated with basophilic inclusions, considered by us as a calcified protein substance. In the depth of the bone matrix, these inclusions took on the appearance of blurred stripes running parallel to the lines of adhesion. In the areas of beams’ discomplexation in the intertrabecular spaces, there were areas of loose fibrous tissue depleted of cellular elements with a predominance of sinusoidal cavities interspersed with fields of fibrous tissue and clusters of cells of the osteogenic pool. Single osteoclasts forming shallow resorption lacunae were also found. The osteoid has increased in size and is represented unevenly in the form of light-pink loose mesh-fibrous masses, which actively filled the defects of the bone substance formed as a result of osteolysis processes, as well as along the newly formed bone beams in the form of dense bands with a parallel-fibrous structure. In the central part of the trabecular array, there was a decrease in the lumen of the bone marrow cavities due to the appositional growth of bone tissue, which is confirmed by numerous (up to 7–11) arc-shaped lines of adhesion. In the bone marrow cavities, the growth of fibrous tissue with the phenomena of edema, loss of protein masses in areas of fibrosis and depletion of cellular elements in the central zone was detected (fig. 1D). The area of fibrous tissue increased by 6 times compared to the control. In vessels, in the area of initial fibrosis, paresis of the wall and necrosis of the endothelium were noted. Cellular elements were preserved in the form of clusters and single-row bands, mainly along the periphery of the cavities, and were surrounded by sharply expanded full-blooded vessels. During histomorphometry, the stellate volume of bone marrow cavities ( $V^*$ ) decreased by 70 times.

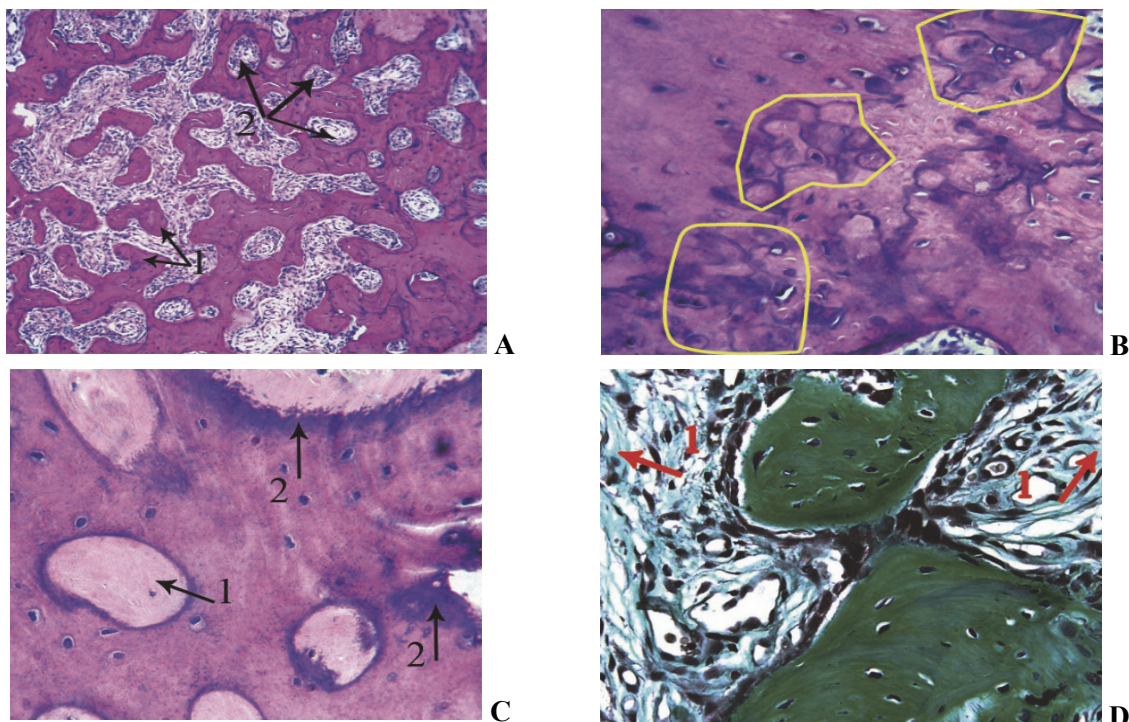


Fig. 2. The structure of bone tissue of the lower jaw after exposure to pamidronic acid for 90 days. A. Dyscomplexation of beams and increase of intertrabecular spaces (1); bone marrow cavities closed by lamellar bone (2). Staining with hematoxylin and eosin. x 100. B. Zones of osteosclerosis (highlighted in yellow), which include Haversian canals and foci of osteocytic osteolysis, are covered by compact bone tissue. Staining with hematoxylin and eosin, x100; C. Cortical plate with expanded Haversian canals filled with osteoid masses (1); areas of intense basophilia (2). Staining with hematoxylin and eosin x 400. Fibrosis of bone marrow cavities. Masson-Goldner staining, x 400.

During the microscopic examination in the specimens of the animals' fourth group, a heterogeneous picture of the spongy bone structure was observed. There were old thickened bone beams, depleted of osteocytes, which alternated with thinned crossbars with smoothed edges, which indicated the development of osteodystrophic processes. Newly formed trabeculae were characterized by different width and shape, forming accumulation of bone substance with chaotic branching, forming small, medium and wide intertrabecular spaces (fig. 2 A)

When staining according to Romanovsky-Giemza, variability of the shades of the studied trabecular network was noted. In areas with intense basophilia, cracks and chips along the lines of gluing were detected. The phenomenon of structural disorganization of bone beams has acquired a diffuse character, which is confirmed by all the determined morphometric indices that characterize the microarchitectonics of trabecular bone (high variation range). In the cortical plate and on the periphery of old trabeculae, an increase in the area of osteocytic osteolysis was noted in comparison with the indices of the third control group. Part of the osteocytic lacunae subjected to osteolysis, merging together and opening into the interbeam space, formed bone tissue defects that were partially filled by loose osteoid masses. As a result, fields of small and acellular non-calcified osteoid with preserved osteocytic lacunae with signs of lytic processes and protein-osteoid content were formed. A denser mineralized osteoid was found in the areas where there was a cluster of cells along the edge of the trabeculae. In the zones of thinned trabeculae with few osteocytes, the osteoid was located in thin strips with smoothed edges. Its surface was by 11.95 % ( $p < 0.05$ ) higher than the similar index of the third control group. Osteoclasts were mainly represented by old forms forming shallow individual resorption lacunae. Haversian canals in the zones of active reconstruction are expanded, filled with protein masses, which are replaced by osteoid with formation of lamellar bone along the inner edge of the canal. An increase in the fibrous component with a decrease in the number and desolation of the lumen of the vessels and its infiltration by protein masses was noted in the bone marrow cavities. On the edge of bone marrow cavities, a granular eosinophilic mass surrounding vascular-fibrous structures was observed to be pushed out by dense osteoid tissue with the appositional formation of lamellar bone, which led to the reduction of bone marrow spaces. During the histomorphometric analysis, the stellate volume of bone marrow cavities decreased by 2.6 times compared to similar indices of the third control group. As a result of the study performed in laboratory white rats of the second and the fourth groups pamidronic acid at the dose of 63 mg/kg, pronounced changes in the course of osteogenic processes were revealed. During the first 30 days of exposure, a pronounced osteostimulating effect was observed in animals of group 2, which was combined with negative manifestations caused by the osteophilic effect of the drug: bone tissue remodeling processes were carried out by osteocytic remodeling, including osteocytic osteolysis ("lacunary honeycombs", nid d'abeilles), against the background of low osteoclastic activity observed throughout the experiment. Hypoxia, caused by toxic vasculopathy in the form of paresis, desolation and necrosis of the vessels' endothelium, created conditions for the occurrence of fibrosis processes in bone marrow spaces against the background of focal aseptic necrosis, which is characteristic of this group's drugs [8,12,13].

In the late period of the study (90-day exposure to the drug), an increase in negative effects caused by the substance under study was noted, which were manifested in the strengthening of the histoarchitectonics' destructuring phenomena of the lower jaw and the slowing down the maturation of the bone matrix. It was manifested in:

In the late period of the study (90-day exposure to the drug), an increase in negative effects caused by the substance under study was noted, which were manifested in the strengthening of the histoarchitectonics' destructuring phenomena of the lower jaw and the slowing down the maturation of the bone matrix. It was manifested in:

– an increase in discomplexed zones in newly formed trabeculae and the appearance of thinned crossbars in a mature trabecular array, which indicates focal osteodystrophic processes;

– violation of the tinctorial properties of the examined bone – intense basophilic staining, cracks and chips along the lines of gluing, which appeared during the microtomy of the specimen, indicating a weak mutual connection of bone generations that arose at different times [6];

– a statistically significant increase in the areas of non-calcified osteoid by 1.5 % ( $p < 0.05$ ), osteocytic osteolysis and osteonecrosis by 6.5 % and 10 % in comparison with similar indices of the previous period, which indicates a decrease in the intensity of osteogenic processes;

– intensive deposition of the mineral component, which potentiates the phenomena of hypoxia, confirmed by the presence of basophilic inclusions and petrificates in all zones of the bone matrix (probably compounds of calcium phosphate and pamidronic acid that have not undergone decalcification) [6, 12];

– an increase in the area of the fibrous component in the bone marrow cavities by 50 % ( $p < 0.05$ ), in comparison with the similar index of the previous term, a decrease in vascularization and emptying of

vessels in the bone marrow cavities, arising of osteosclerosis zones in the areas of osteocytic osteolysis, in the surrounding osteon systems, and also in the intertrabecular spaces.

Thus, the influence of the studied substance led to blocking the activity of the osteoclastic component, which shifted the processes of bone remodeling to the side of osteocytic remodeling as a compensatory process. Hypoxia caused by toxic vasculopathy and mechanical compression of the mineral component, which is intensively deposited in the studied bone structures, led to the development of focal osteonecrosis, myelofibrosis with transition to osteometaplasia processes with subsequent osteosclerotic and osteodystrophic changes. Hyperostosis, determined by the superiority of the processes of hypoxically distorted osteosynthesis over the processes of resorption, led to the formation of afunctional loose bone masses. The dynamics of this pathology are similar to the processes that develop in ossifying osteitis, and can be considered as a primary lesion of the mandibular bone (zero stage of osteonecrosis) before the onset of open clinical pathological forms [7, 13].

### Conclusions

1. The drug of the aminobisphosphonate group – pamidronic acid in the dose of 63 µg/kg at the end of the 30th day of the experiment has osteostimulating properties, despite the initial manifestations of toxic-hypoxic damage caused by intensive deposition of the mineral component and direct toxic effect on the vascular component, which leads to the launch of aseptic osteonecrotic processes.
2. The main mechanism of reconstruction of the lower jaw with aminobisphosphonate load is osteocytic remodeling.
3. Administration of pamidronic acid at the dose of 63 µg/kg to laboratory white rats for 90 days resulted in myelofibrosis and focal osteosclerotic and osteodystrophic changes. The dynamics of pathology development are similar to the processes that develop in ossifying osteitis, and can be considered as the zero stage of osteonecrosis in the mandible.

### References

1. Avrunin AS. Osteositsitarnoye remodelirovaniye: istoriya voprosa, sovremennyye predstavleniya i vozmozhnosti klinicheskoy otsenki. *Travmatologiya i ortopediya Rossii*.2012; 63, 1: 128–134. <https://doi.org/10.21823/2311-2905-2012-0-1-149-156> [in Russian]
2. Volkov AV, Bolshakova GB. Gistomorfometriya kostnoy tkani v regenerativnoy meditsine. *Klinicheskaya i eksperimentalnaya morfologiya*. 2013; 3: 65–72. <http://www.morfolhum.ru/journal/2013-no-3/> [in Russian]
3. Kutya S.A. «Zvezdchatyy obyem» – effektivnyy gistomorfo-metricheskyy pokazatel stepeni soyedinennosti elementov trabekulyarnoy seti. *Tavricheskyy mediko-biologicheskyy vestnik*. 2012;15(4):212–214. <http://dspace.nbuv.gov.ua/handle/123456789/60851> [in Russian]
4. Peshkov M.V. Decalcification in histological laboratory technique. *Archive of pathology*. 2012; 6: 44–46. <tps://www.mediasphera.ru/issues/arkhivpatologii/2020/6/downloads/ru/1000419552012061043> [in Russian]
5. Chastota vstrechayemosti bisfosfonatnogo osteonekroza (analiz arkhivnykh dannykh). *Melnikova S.YU. i dr. Mezhdunarodnyy studencheskiy nauchnyy vestnik*. 2016; 4–1: 120–121. URL: <https://eduherald.ru/ru/article/view?id=15841> [in Russian]
6. Demkovich A, Bondarenko Y, Hasiuk P. Cytokinogenesis disorders in mechanisms of the experimental perodontitis development and their correction by flavonol *Wiadomości Lekarskie*. 2022. 75, 1: 47–51. [doi.org/10.36740/WLek202201108](https://doi.org/10.36740/WLek202201108)
7. Bell C. and Soukup J. Histologic, Clinical, and Radiologic Findings of Alveolar Bone Expansion and Osteomyelitis of the Jaws in Cats *Veterinary Pathology* 2015, Vol. 52(5) 910–918 <https://doi.org/10.1177/0300985815591>
8. Cakarar S, Selvi F, Keskin C. Bisphosphonates and bone. In: *Orthopedic Surgery*. Z. Al-Aubaidi (ed.). Tech.2012;141–7. <https://doi.org/10.5772/26333>
9. Dempster DW, Compston JE, Drezner MK, Glorieux FH. Standardized Nomenclature, Symbols, and Units for Bone Histomorphometry: A 2012 Update of the Report of the ASBMR Histomorphometry Nomenclature Committee. *J. of Bone and Mineral Research*. 2013; 28(1):1–16. <https://doi.org/10.1002/jbmr.1805>
10. Directive 2010/63 was amended in 2019 by Regulation (EU) 2019/1010 to incorporate ambitious goals for reporting and transparency to help progress towards the ultimate goal of total replacement of animal use: Member States shall collect and make publicly available, on an annual basis, statistical information on the use of animals in procedures, including information on the actual severity of the procedures and on the origin and species of non-human primates used in procedures. 2019; [https://translated.turbopages.org/proxy\\_u/en-ru.ru.85d3297c-6362f8a2-1001fe06-4722d776562/https/norecopa.no/legislation/statistics](https://translated.turbopages.org/proxy_u/en-ru.ru.85d3297c-6362f8a2-1001fe06-4722d776562/https/norecopa.no/legislation/statistics)
11. McClung M, Harris S. Bisphosphonate therapy for osteoporosis: benefits, risks, and drug holiday. *Am J Med*. 2013 Jan;126(1):13–20. [doi: 10.1016/j.amjmed.2012](https://doi.org/10.1016/j.amjmed.2012).
12. Mostovoy SO, Shulgin VF, Maksimova EM, Nauhatsky IA. Mineralizing process and morphological structure of the femoral bone in rats under influence of aminophosphonates. *J. Exp. Integr. Med*. 2014; 4(2):81–4. <https://doi.org/10.5455/jeim.260214.br.019>.
13. Salvatore L, Ruggiero, MD, Thomas B. Dodson. American Association of Oral and Maxillofacial Surgeons Position Paper on Medication-Related Osteonecrosis of the Jaw—2014 Update American Association of Oral and Maxillofacial Surgeons. *J Oral Maxillofac Surg*. 2014;72:1938–1956, <http://doi.org/10.1016/j.joms.2014.04.031>.
14. Sven O, Christoph P. Further development of the MRONJ minipig large animal model *J Craniomaxillofac Surg* 2017 Sep; 45(9):1503–1514. <https://doi.org/10.1016/j.jcms>.
15. Tamaoka J, Takaoka K. Osteonecrosis of the jaws caused by bisphosphonate treatment and oxidative stress in mice. *Exp Ther Med*. 2019 Feb;17(2):1440–1448. <https://doi.org/10.3892/etm.2018.7076>.

Стаття надійшла 19.11.2021 р.